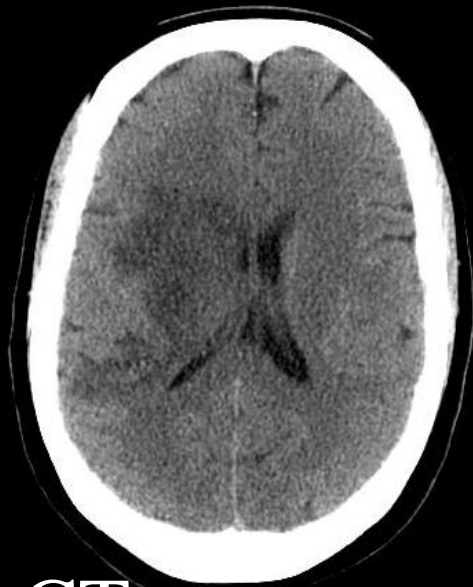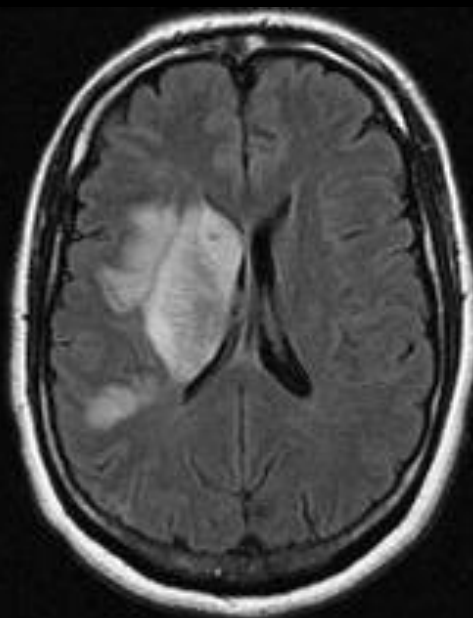

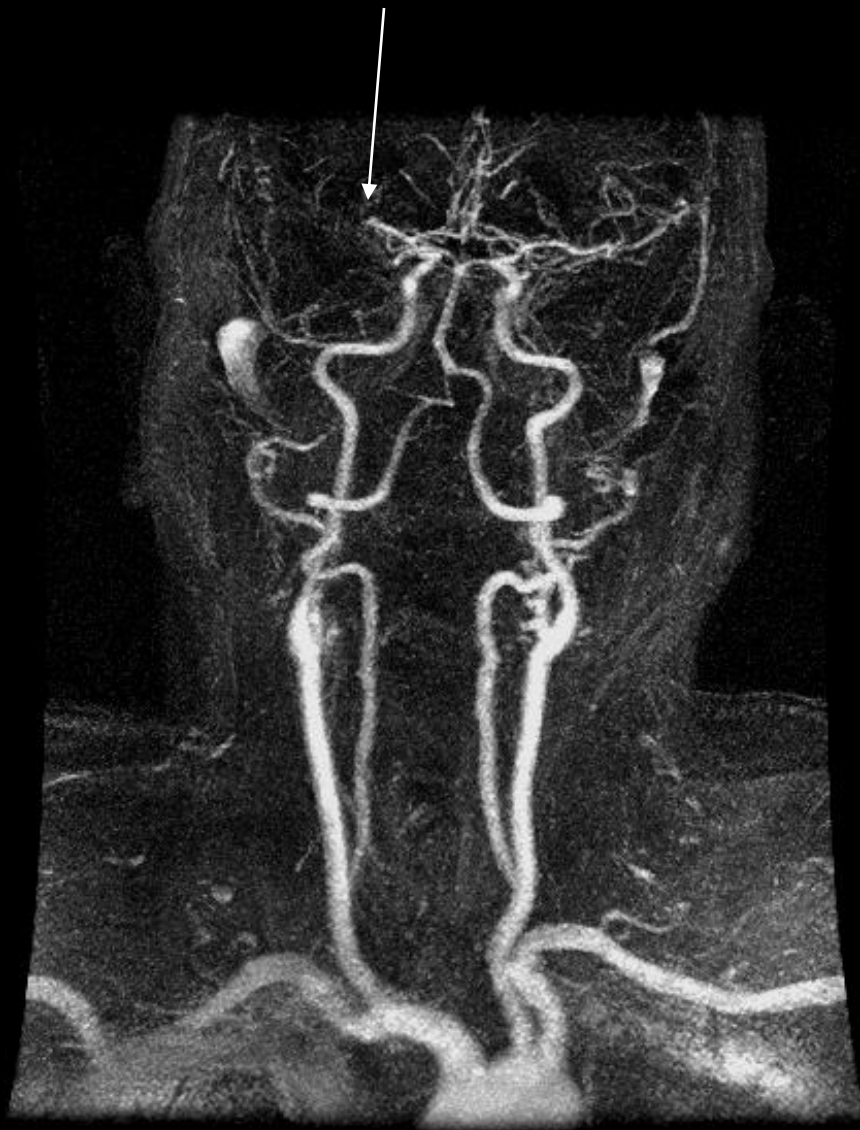


CT



MR



These images are used to help diagnose a patient who may be suffering a stroke.

*(left images)* The CT and MR images show dead brain tissue the day after a major stroke, caused by a blockage in one of the arteries that feeds the brain.

*(right image)* This image shows the arteries from the heart to the brain. The arrow points to the area of the stroke, where the artery is blocked.